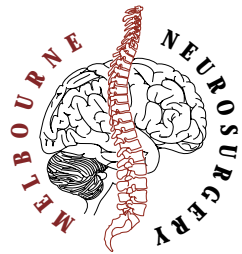
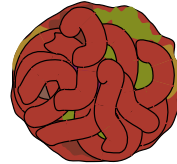


INFORMATION LEAFLET

CAVERNOUS HAEMANGIOMA (Cavernoma)



WHAT IS A CAVERNOUS HAEMANGIOMA ?



A Cavernous Haemangioma (Cavernoma) is a vascular lesion that appears in the brain in a small group of people. They are usually small but can get quite large. They are usually single but may be multiple. They are felt to grow in size in two ways, the vascular structures within them probably grow by budding off new areas and at the same time small micro haemorrhages increase the size of the lesion. The final structure is made of old blood as well as the vascular component.

IS IT A TYPE OF TUMOUR ?

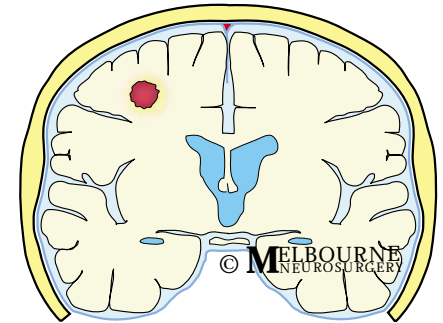
Even though this may grow it is not a tumour.

WHERE DO THEY OCCUR ?

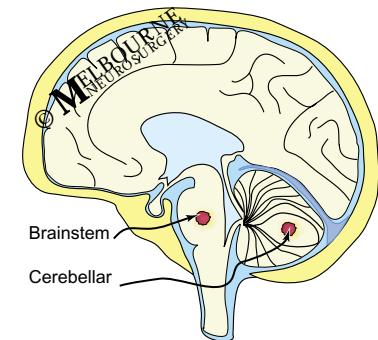
They can occur anywhere in the brain. This includes the cerebellum and brainstem.

HOW DO THEY AFFECT YOU ?

This depends predominantly on the location of the cavernoma. They can be divided up into the lesions in the periphery of the brain (as shown in the illustration top right) or the lesions in the deep part of the brain or brainstem (see below)



Section through brain
with cavernoma in typical location



Section through brain
showing brainstem and cerebellar lesions

Peripheral lesions

These may not produce any symptoms and may be found when a Cat scan or M.R.I. scan is done for another reason. If they are causing symptoms the common problem is that the blood that leaks from the vessels is irritant to the brain and may cause epilepsy(seizures).

The other problem is that the bleeding may not just be a small local leak(which here causes little problems) but a large bleed which could cause stroke like symptoms (weakness).

Deep and Brainstem lesions

These cause different problems to the lesions above because of their location.

In the deep part of the brain and the brainstem, everything important is all packed closely together so that, a small lesion here can produce a large number of symptoms. If deep in the brain it is likely to produce weakness or numbness.

If in the brainstem it can produce not only the above but also problems with walking, balance, and double vision. The cerebellar lesions can produce problems with balance also.

WHAT IS THE RISK OF BLEEDING ?

There is generally a very low risk of these lesions bleeding and when they do the amount of bleeding is usually small. If the lesion is in the periphery of the brain this doesn't often produce a problem. If this is in a deep lesion and the cavernoma is increasing in size it may cause problems.

WHEN ARE THEY TREATED ?

Bleeding

If you have had a small bleed and the lesion is in the periphery of the brain we would probably observe the lesion with scans to make sure it is not enlarging.

If the bleed is large we would likely remove the blood clot and the lesion with it.

If the bleed is small but the lesion is in an important part of the brain we may consider removing it. This depends on whether surgery is safe in that part of the brain. Sometimes the lesion is so deep in an important part of the brain that we cannot get to it without producing severe damage. These lesions cannot be treated with surgery.

Epilepsy

These lesions can be the focus for epilepsy and this can be confirmed with a special test to look at the electrical activity in the brain (E.E.G).

Epilepsy can be controlled with medication in most instances and surgical removal is not required. If the medications cannot control the epilepsy or you cannot take the medication then surgical removal of the lesion and the blood stained brain around it may stop the fitting.

HOW ARE THEY DIAGNOSED ?

Either because you have had some imaging to show it or it was found at surgery.

CAT SCAN

This is usually first. This is a computerised X ray of your brain that may show the lesion or the blood clot around it

M.R.I. (Magnetic Resonance Imaging)

This is the next test. It produces pictures like the CAT scan but they are generated using a magnetic field and not using radiation. The cavernoma has a typical appearance on the M.R.I. scan. Sometimes this is not conclusive and surgery may be suggested to make a diagnosis

SURGERY

Sending the lesion to the pathologist to look at under the microscope is the only sure way to confirm that the lesion on the scans is a cavernoma.

You are referred to a specialist after the CAT scan in most cases and they organise any further investigations.

The common specialists to be referred to are:

Neurosurgeons

Neurologists

WHAT TYPE OF SURGERY IS REQUIRED ?

The procedure is generally called a CRANIOTOMY (see leaflet)

ARE THERE ANY OTHER TREATMENTS ?

Surgical excision is the only tested remedy

FOR ABOVE PROCEDURES SEE THE RELEVANT PROCEDURE LEAFLET

MELBOURNE
NEUROSURGERY
neurosurgery.com.au

545 ROYAL PARADE
PARKVILLE VIC 3052

PHONE 03 9387 - 4400

FACSIMILE 03 9387 - 4600

MELBOURNE NEUROSURGERY
PTY LTD
ACN 082 289 316

Disclaimer. This brochure is to provide general information and does not replace a consultation with your doctor.

© This brochure is copyright. No part of it may be reproduced in any form without prior permission from the publishers.